



PATIENT

Casey Mazzer

SPECIES

Canine

BREED

Goldendoodle

SEX

Male Neutered

AGE

9 years

WEIGHT

53lbs

INTERPRETED BY

Maggie Machen Lamy,
DVM, DACVIM
(Cardiology)

IMAGING PERFORMED BY

Jessica Miller

HOSPITAL NAME

Bergen Passaic
Animal Hospital

REFERRING VET

Dr. Talik

INVOICE

25060

DATE

6/29/22

PRESENTING CLINICAL SIGNS

History: Heart appeared congested on radiographs.
-Current medications: Prednisone, cough tabs.
-Sedation: Torb & Midaz.

ECHOCARDIOGRAM FINDINGS

2D, m-mode, color flow and doppler imaging is available. Severe left ventricular dilation with akinetic free wall and hypokinetic septum and diminished systolic function. Decreased LV wall thickness with increased sphericity. Marked left atrial enlargement. The mitral valve appears thickened with no obvious prolapse into the left atrial lumen. Moderate to severe eccentric mitral regurgitation secondary to annular stretch. Normal velocity. Mild tricuspid regurgitation. Moderate right atrial and ventricular dilation. TR velocity consistent with mild pulmonary hypertension. The aortic valve is normal in morphology and mobility. No subvalvular ridge present; normal LVOT velocity. Trace aortic insufficiency. Normal pulmonic valve with trace pulmonic insufficiency seen. No pericardial or pleural effusion noted. Hepatic congestion noted on subcostal views. No obvious cardiac tumors.

CARDIAC CHART

CANINE CARDIAC PARAMETERS	MR VMAX (m/s)	TR VMAX (m/s)	LA/AO (Boon method)	LA/AO (Heart Base; Swe)	FS (%)	EF (%)	EPSS (cm)
NORMAL PARAMETER	4.5-5.5	<2.7	1.3	<1.6	28-40	40-100	<0.6
PATIENT	5.1	3.0	NM	2.8	12	20	1.0
CANINE CARDIAC PARAMETERS	HR (BPM)	AV VMAX (m/s)	PV MAX (m/s)	BODY WEIGHT (kg)	LA 2D short axis Base view (cm)	LVIDd Avg; 2D and m-mode short axis (cm)	LVIDs Avg; 2D and m-mode short axis (cm)
NORMAL PARAMETER	50-100	0.7-1.7	0.7-1.6	BELOW	BELOW	BELOW	BELOW
PATIENT	160	1.2	1.1	24.0	5.9	7.7	6.8
*Normal chamber parameters expressed as a mean value (SD)				3	1.27 (5.3)	2.46 (2.46)	1.36 (5.5)
BODY WEIGHT DEPENDENT PARAMETERS				5	1.40 (4.5)	2.74 (5.2)	1.60 (4.7)
<i>*Note: All measurements based upon multi-modal images and methods. An average value is reported.</i>				10	1.50 (3.8)	3.27 (3.5)	2.06 (3.1)
				15	1.83 (2.0)	3.71 (2.4)	2.43 (2.1)
				20	2.02 (1.9)	4.14 (2.2)	2.80 (2.0)
				25	2.18 (2.4)	4.48 (2.9)	3.10 (2.5)
				30	2.33 (3.3)	4.83 (3.9)	3.39 (3.4)
				35	2.48 (4.3)	5.17 (5.0)	3.69 (4.5)
				40	2.62 (5.2)	5.48 (6.1)	3.96 (5.4)
				50	2.88 (7.1)	6.07 (8.3)	4.46 (7.4)

Adapted from June Boon, Veterinary Echocardiography, 1998
Rishniw M and Hollis NE, J Vet Intern Med 2000; 14:429-435
Hansson et al, Vet Rad and Ultrasound 2002
Bonagura et al. Echocardiography: principles of interpretation, Vet Clin North Am 15:1177, 1995

INTERPRETATION OF THE FINDINGS & FURTHER RECOMMENDATIONS

Unfortunately, this patient has significant cardiomyopathy and systolic dysfunction. This is causing dilation and volume overload of both the left and right heart resulting in insufficiency of the mitral and tricuspid valves. The quantity of MR is significant, and a concurrent valve issue cannot be ruled out. Regardless, the severity of dysfunction and pump failure is severe, and the patient is at high risk for decompensating into congestive failure. Patient will always be at risk for



PATIENT	right and/or left-sided CHF, development of arrhythmias/syncope and/or sudden death going forward. Hepatic congestion is noted, which is consistent with early CHF.
Casey Mazzer	
SPECIES	Systolic failure can be primary in nature (DCM) or secondary to taurine deficiency, myocarditis, hypothyroidism, tachycardia-induced cardiomyopathy, or infiltrative disease such as lymphoma. While primary disease is certainly possible, consider testing for primary causes that may be treatable. A troponin (cTnI) level can be submitted to further investigate infiltrative/inflammatory contribution (myocarditis). Additionally, a taurine level may be helpful (screen for malabsorption issue), and a thorough diet history given the recent correlation with grain free/boutique brand/exotic ingredient diets. Finally, further systemic evaluation for underlying infiltrative contribution such as neoplasia is also reasonable (abdominal ultrasound, etc.).
Canine	
BREED	
Goldendoodle	
SEX	Regardless of cause, prognosis is guarded to poor at this stage in the disease process, with an average survival time of <6 months. The only treatable cause of systolic failure is diet/taurine deficiency, which is uncommon on commercially formulated dog foods. If the diet is of concern, highly recommend immediate diet change and taurine supplement regardless of blood taurine results. Please see the FDA website for more information.
Male Neutered	
AGE	
9 years	Immediate institution of full cardiac supportive medications is recommended as below due to high risk for decompensation. This includes low dose therapy. Cases of systolic failure are at high risk for malignant tachyarrhythmias (such as VT or rapid AF) and sudden death, and this should be expressed to the owner. Activity restriction is advised, and a baseline ECG recommended.
WEIGHT	
53lbs	
INTERPRETED BY	Elective anesthesia is not advised due to high risk for complications.
Maggie Machen Lamy, DVM, DACVIM (Cardiology)	Omega fatty acid supplementation and mild salt restriction may be of some long-term benefit. Monitor for development of a cough, worsening labored breathing, abdominal distention, exercise intolerance or collapse episodes in the future. Monitoring of sleeping breathing rates at home is recommended to assess response to medications and recurrence of CHF in the future.
IMAGING PERFORMED BY	PLAN: Discontinue Prednisone unless necessary. Baseline BP/ECG recommended. Initiate aldosterone antagonist Spironolactone 1-2mg/kg PO q12h. Institute furosemide 1mg/kg PO q12h. Institute Pimobendan 0.3mg/kg PO q12h. Institute taurine 1000mg PO q12h. Diet history/change as discussed.
Jessica Miller	
HOSPITAL NAME	Monitor a renal panel and blood pressure in 1-2 weeks to ensure tolerance. If BP >130mmHg, institute ACEI 0.5mg/kg PO q12h. Consider cTnI, taurine level, AUS as discussed above.
Bergen Passaic Animal Hospital	
REFERRING VET	A recheck echocardiogram is recommended in 4-6 months to screen for progression, sooner if clinical issues arise in the interim.
Dr. Talik	
INVOICE	
25060	
DATE	
6/29/22	



PATIENT

Casey Mazzer

SPECIES

Canine

BREED

Goldendoodle

SEX

Male Neutered

AGE

9 years

WEIGHT

53lbs

INTERPRETED BY

Maggie Machen Lamy,
DVM, DACVIM
(Cardiology)

**IMAGING
PERFORMED BY**

Jessica Miller

HOSPITAL NAME

Bergen Passaic
Animal Hospital

REFERRING VET

Dr. Talik

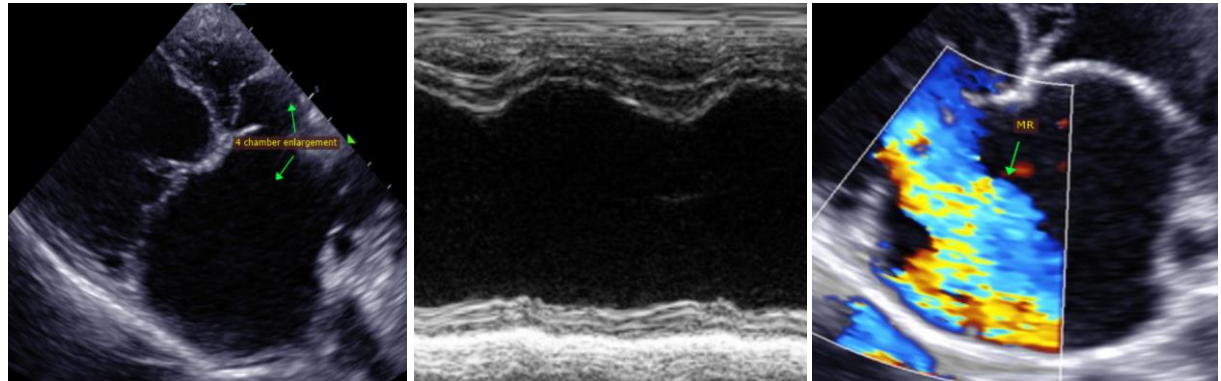
INVOICE

25060

DATE

6/29/22

IMAGES



The information and recommendations provided are based on the images presented by the referring veterinarian. No evaluation can be communicated regarding pathology that was not visible in the image/video clips provided.

Thank you for this referral. This report was generated using transcription software, and minor dictation errors may be present. If the clinical or image interpretation does not parallel your findings or if I can be of any further assistance, please contact me.

Maggie Machen Lamy, DVM
Diplomate of the American College of Veterinary Internal Medicine (Cardiology)
info@sonopath.com